



## How to Improve Access to Subgingival Biofilm with Curved Ultrasonic Instruments

by Dani Botbyl, RDH • [dani.botbyl@dentsply.com](mailto:dani.botbyl@dentsply.com)

Over the last 60 years, ultrasonic equipment and the evidence for its use have evolved tremendously. Today, ultrasonics provide greater utility subgingivally, including the use of thin, ultra-thin, straight, and curved ultrasonic instruments for light calculus removal and biofilm disruption. In essence, ultrasonic instrumentation has progressed beyond use for only calculus removal and can now be categorized into traditional and contemporary approaches (Table 1).<sup>1</sup> Prompting the more contemporary use of ultrasonics were Holbrook and Low when, in the

▼ Table 1

Traditional	Contemporary
Thick diameter inserts	Thin or ultra-thin diameter inserts; straight and curved designs
Subgingival access limited	Subgingival access is superior
Moderate to heavy calculus removal	Light calculus removal; focus on biofilm removal
Instrument contacts calculus	Instrument contacts cementum/dentin
Medium to high power settings typical	Low-medium power settings typical
Basic level of knowledge/skill and short 'time on task' to achieve competence	Higher level of knowledge/skill and a longer 'time on task' to achieve competence
Complete debridement requires the use of hand instruments	Complete debridement possible with ultrasonic
Client/patient comfort challenging	Client/patient comfort most usual

1990s, they examined thin, straight, and curved ultrasonic inserts for the negotiation of deep periodontal pockets.<sup>2</sup> Soon after, Dragoo explored this concept using only left and right curved designs and showed their superiority in offering better access to deep periodontal pockets.<sup>3</sup> These thin curved inserts produced more effective calculus and plaque removal with the least amount of root surface damage when compared to hand instruments and traditional thick ultrasonic inserts.<sup>3</sup> Drisko's benchmark review article on ultrasonic technology for non-surgical periodontal therapy further confirmed these findings.<sup>4</sup> The development of thin,

straight, and curved ultrasonic instruments combined with the research is perpetuating a shift towards ultrasonics as a first choice for periodontal debridement because of their perceived advantages.<sup>5-9</sup>

Despite the compelling evidence supporting the advantages of ultrasonic periodontal debridement with contemporary-type instruments, it appears that specifically thin, curved ultrasonic instruments are underutilized in clinical practice. A 2014 Canadian study suggests that approximately 85% of recent dental hygiene graduates do not use curved ultrasonic instruments.<sup>1</sup> Admittedly, curved designs are less intuitive than straight designs, and many clinicians report a lack of knowledge of and confidence with their use. Maximizing the benefits of ultrasonic instrumentation is multifactorial. Instrument adaptation is certainly not the only key to success but it is an important one. Figure 1 is intended to "demystify" the adaptation of left and right curve inserts, as effective implementation of these "periodontal gems" provides a compelling option for enhancing the disruption of biofilm.

**Figure 1. Selecting the CORRECT Curved Insert**

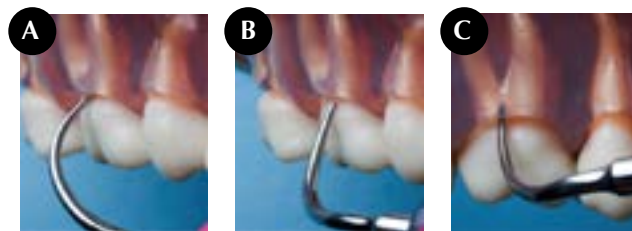


Figure 1a: curved right insert; Figure 1b: curved left insert; Figure 1c: curved left insert

The best insert choice for Q1 posterior buccal is a left curved instrument. In vertical orientation, the point of the curved right instrument (Figure 1a) contacts the tooth surface. Continued subgingival placement on the buccal surface of this tooth with this insert would only lead to increased point-to-root contact. An overwhelming advantage of curved ultrasonic instruments is the ability of the back convex surface of the active tip to conform to any concave tooth/root surface. Therefore, when deciding between a curved right and left insert, choosing the instrument whereby the back can adapt to the tooth/root surface (Figure 1c) will improve access. In some areas, such as the distals of many posterior teeth, the back cannot physically be adapted; in these cases the lateral is the surface of choice (Figure 1b). *Continued...*

## Focus: Ultrasonics - Revolutionizing Periodontal Therapy

How To Improve Access...cont'd

### Figure 2. Selecting the ORIENTATION of a Curved Instrument

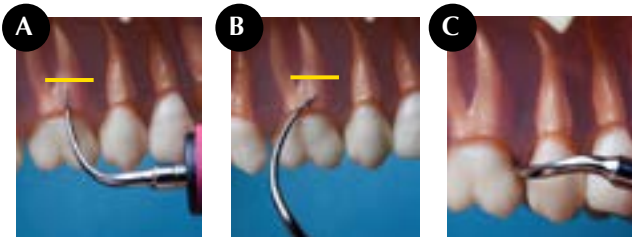


Figure 2a

Figure 2b

Figure 2c

To maximize subgingival access the most upright, vertical orientation is needed (Figure 2a). Vertical orientation positioned more obliquely will not access the same depth (Figure 2b). Note the differences in instrument point location to the yellow line of Figure 2a and Figure 2b. Transverse orientation (Figure 2c) is used to access supragingival deposits and is especially effective under contact points.

### Figure 3. Sequencing of a Curved Instrument

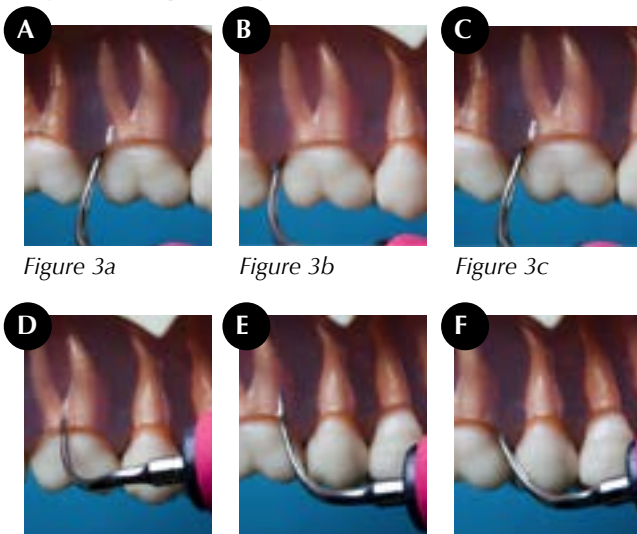


Figure 3a

Figure 3b

Figure 3c

Figure 3d

Figure 3e

Figure 3f

Subgingival access on 16 buccal is best done with a curved left insert. Using vertical orientation, insert the curved left instrument at the DB line angle (Figure 3a). Work distally as far into the distal subgingival space as allowable (Figure 3b). Maintain as much of an upright vertical position (vertical orientation) as possible. Compromising your vertical orientation will compromise access. Once debridement is complete in the subgingival distal space, work back towards the DB line angle (Figure 3c), past this line angle now instrumenting the direct buccal surface (Figure 3d). At the MB line angle (Figure 3e), while maintaining vertical orientation, start to direct the ultrasonic instrument into the mesial subgingival space (Figure 3f). Note: ideal access of interproximal areas may require a slight oblique

instrument position (Figure 3g) but this change in direct vertical orientation should not be used until well past the line angles. Failure to do so increases risk for poor access interproximally.

### Figure 4. Accessing a FURCATION using a Curved Instrument

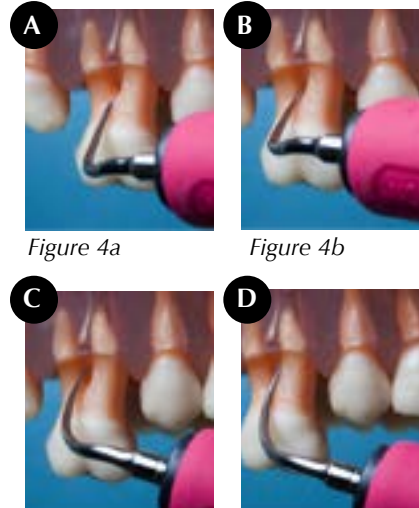


Figure 4a

Figure 4b

Figure 4c

Figure 4d

Access to 16 buccal furcation is best done with a curved left insert leading with the back surface of the instrument. The convex back surface combined with the lateral surfaces of a curved instrument are the focus and, depending on classification of furcation, tooth position, and client-operator position, many combinations of the back and lateral surfaces may present. As a reminder, the back should be used when at all possible. This series of images shows the back of the curved instrument leading into the dome of the furcation (Figure 4a). During treatment, the clinician should keep the active tip adapted and use a combination of suitable stroke types to debride as much of the dome that is exposed (Figure 4b). Once the dome has been fully accessed, shift to the mesial surface of the distal root adapting either the back or lateral surface of the curved instrument (Figure 4c). The final required step is placement of the lateral surface of the curved insert on the distal surface of mesial root (Figure 4d).

### References

- Asadoorian J, Botbyl D, Goulding MJ. Dental hygienists' perception of preparation and use for ultrasonic instrumentation. *Int J Dent Hyg*. 2014. DOI: 10.1111/idh.12092
- Holbrook T, Low S. Power-driven scaling and polishing instruments. In *Clark's Clinical Dentistry, Volume 3, Chapter 5A*. Edited by Hardin J. Philadelphia: JB Lippincott; 1991. pp 1-24.
- Dragoo M. A clinical evaluation of hand and ultrasonic instruments on subgingival debridement. Part 1. With unmodified and modified ultrasonic inserts. *Int J Periodontics Restorative Dent*. 1992;12(4):310-23.
- Drisko C. Scaling and root planing without over instrumentation: Hand versus power-driven scalers. *Curr Opin Perio*. 1993;78-88.
- Sliva LB, Hodges KO, Calley KH, Seikel JA. A comparison of dental ultrasonic technologies on subgingival calculus removal: a pilot study. *J Dent Hyg*. 2012;86(2):150-58.
- Drisko CH. Nonsurgical periodontal therapy. *Periodontol* 2000. 2001;25:77-88.
- Khorsravi M, Bahrami ZS, Atabaki MS, Shorkrgozar MA, Shokri F. Comparative effectiveness of hand and ultrasonic instruments in root surface planing in vitro. *J Clin Periodontol*. 2004;31(3):160-65.
- Tunkel J, Heinecke A, Flemmig TF. A systematic review of efficacy of machine-driven and manual subgingival debridement in the treatment of chronic periodontitis. *J Clin Periodontol*. 2002;29(Suppl 3):72-81.
- Kinane DF, Papageorgakopoulos G. Full mouth disinfection versus quadrant debridement: The clinician's choice. *J Int Acad Periodontol*. 2008;10(1):6-9.