



# Contemporary Ultrasonics: Debridement from Start to Finish! A Case Study

by Cheri Wu, RDH, BDS(c)(DH) • [toothfairy@focusondh.com](mailto:toothfairy@focusondh.com) • [www.FocusOnDH.com](http://www.FocusOnDH.com)

As with the profession of dental hygiene, ultrasonic technology and technique have evolved tremendously. The question of whether ultrasonic instrumentation can be used for periodontal therapy from start to finish without the implementation of hand instruments can now be answered with a resounding yes! However, three key elements must be taken into consideration: clinician's knowledge, clinical expertise or skill, and access to ultrasonic equipment that is in good working order and designed for the task at hand. Not all ultrasonic equipment is created equal. It is the dental hygienist's responsibility to bridge the gap between fundamental knowledge and clinical expertise. Thus, participation in hands-on ultrasonic workshops and/or mentoring is important for advancing clinical skills.

Accomplishing ultrasonic debridement successfully from start to finish requires a complement of strategically selected, sequenced, and adapted instruments. A dental hygienist would not use only one hand instrument to complete a whole mouth so why would dental hygiene



▲ Insert selection for case study

treatment with ultrasonics be any different? For many, dental hygiene practice has moved from the more traditional, thicker insert for moderate to heavy deposit removal to the use of curved and specialty inserts, such


as ultra-thin and implant inserts. The use of a variety of inserts allows the clinician better access to the base of the pocket and superior biofilm and calculus removal. To highlight the potential effectiveness of ultrasonic technique and technology, a case study is presented below for a "typical" maintenance client.

### CASE STUDY

The client is a healthy, 53-year-old Asian male on a four-month dental hygiene maintenance schedule. There are no special medical considerations.

### Assessment Data

The client presents with chronic moderate periodontitis in posterior regions evidenced by 2

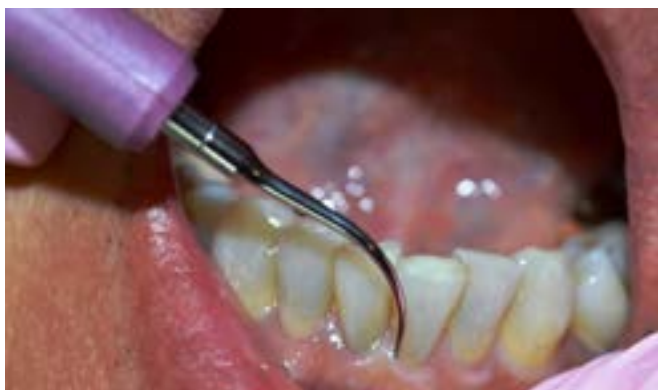

▲ Periodontal chart for Mr. L

Continued...

## Focus: Ultrasonics - Revolutionizing Periodontal Therapy

Contemporary Ultrasonics...cont'd



▲ THINsert with probe-like subgingival insertion

mm to 5 mm probe depths, 1 mm to 3 mm of recession, and Class I–III furcation involvement. Bleeding on probing was noted on the mesiolingual of implant tooth 1.4. Supragingival deposit is moderate on mandibular anteriors with light brown lingual staining, and subgingival deposit is light, increasing in isolated interproximal areas. The dental assessment reveals moderate restorative work including crowns and an implant on tooth area 1.4, tight contact areas with slight retroversion on mandibular anteriors, and intrinsic minocycline staining...

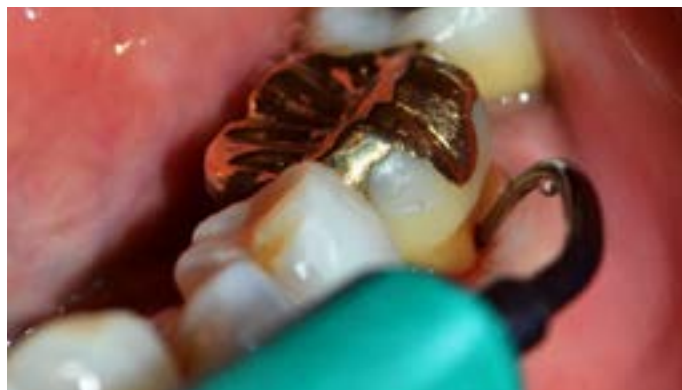### Insert Selection and Sequencing

Insert selection was based on the periodontal assessment. The chosen armamentarium for this case: DENTSPLY Cavitron® Plus ultrasonic unit (magnetostrictive) and DENTSPLY Cavitron® ultrasonic inserts including:

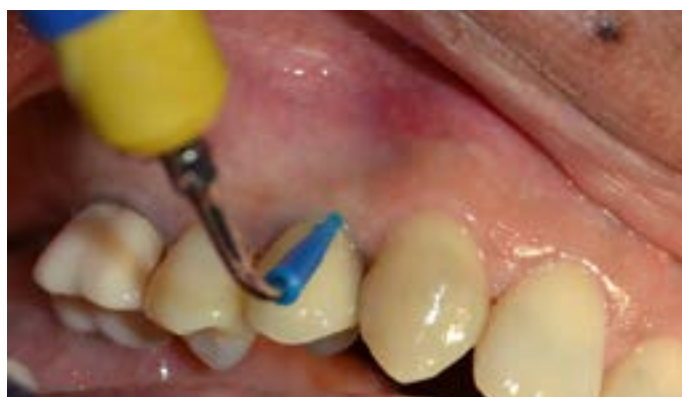- ▶ THINsert (ultra slim)
- ▶ slimLINE 1000 (slim triple-bend)
- ▶ slimLINE Right and Left (curved)
- ▶ SofTip™ Implant Insert

Sequencing was based on efficiency, ergonomics, periodontal assessment, and clinician preference. The choice of power level for effective calculus and biofilm disruption and client comfort is dependent on insert selection and deposit. In general, the lighter the deposit, the lower the power level.

The ultra-slim insert (THINsert) using curette positioning was chosen for deposit removal in tight contact and interproximal areas. With hand instrumentation, the curette and sickle scaler often prove too thick to access tight tooth and gingival tissue. Given its diversity, the ultra-thin insert can be introduced subgingivally on a lower power setting for light deposit and biofilm removal in constrictive tissue areas. The slightly wider diameter and triple bend of the slimLINE 1000 allows for more surface area coverage and better adaptation around line angles with the versatility of



▲ slimLINE left for Class III furcation on tooth 3.6



▲ SofTip™ implant insert on 1.4

varying power levels. Disruption of biofilm on the slightly inflamed 1.4 implant was completed with the SofTip™ implant insert.

The curved slim inserts are specifically designed to adapt to root anatomy and tooth curvatures, and are the instrument of choice for furcation involvement. Inserted in a probe-like position with short activation strokes, the slimLINE Right and Left removed biofilm and light calculus in these areas to complete the client's periodontal therapy. The time to completion was 50 minutes.

### SUMMARY

Dental hygiene and best practices are ever evolving. Ultrasonics are no longer just for calculus removal. With the technology's ability to remove and disrupt biofilm, the creation of thin, ultra-thin, and curved inserts, and the option of using ultrasonics subgingivally on cementum or dentin, it is possible to use ultrasonics as the sole instruments for periodontal debridement. However, technique and equipment matter! As dental hygienists, we have a professional responsibility to maintain current knowledge and skill levels and a responsibility to access technologically sound equipment. If your goal is to "work smarter and not harder" and seek out options that may produce improved clinical outcomes within your practice, why not challenge yourself to take your ultrasonic skills to the next level?